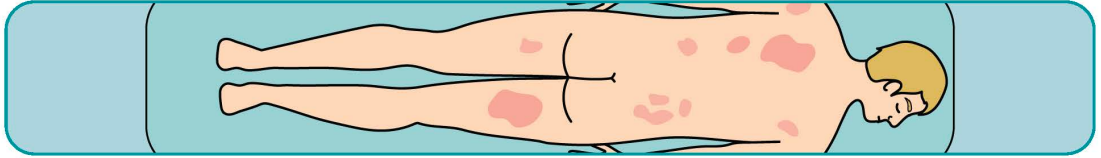


# A-F THINK MF!

A MEMORY AID FOR THE EARLY RECOGNITION OF CUTANEOUS T-CELL LYMPHOMA: MYCOSIS FUNGOIDES / SEZARY SYNDROME

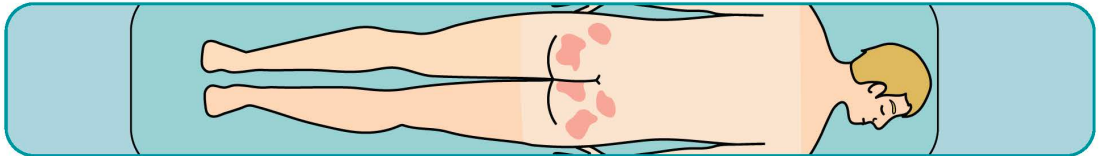
**A**



## ASYMMETRIC

Asymmetric persistent and/or progressive patches/plaques

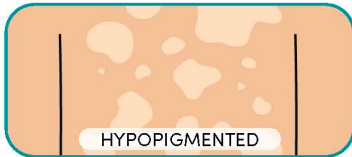**B**



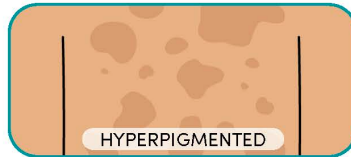## BATHING TRUNK DISTRIBUTION:

Sun-protected sites

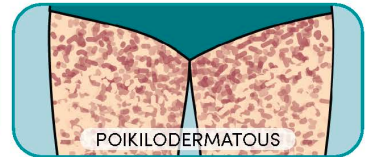
**C**



HYPOPIGMENTED



HYPERPIGMENTED

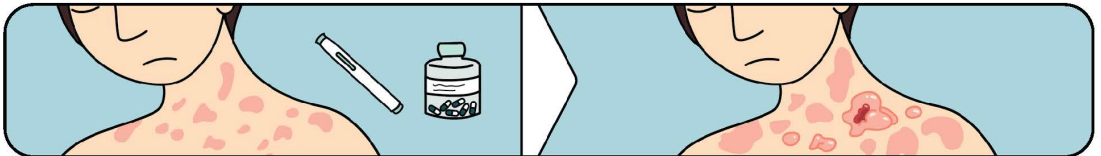


POIKILODERMATOUS

## COLOUR CHANGE IN THE SKIN

Persistent and/or progressive hypo/hyperpigmented patches/plaques or atrophic/telangiectatic patches with discolouration

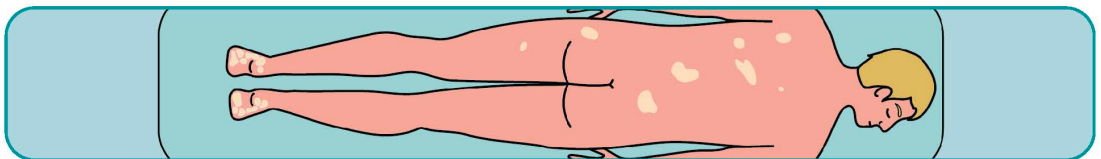
**D**



## DRUG THERAPY CAN WORSEN MF/SS

Drug therapies (e.g. ciclosporin, biologics) can be harmful in patients with undiagnosed MF/SS

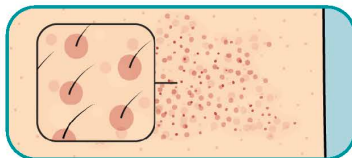
**E**



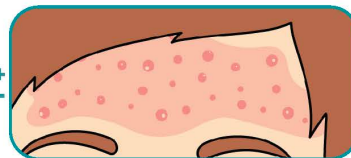
## ERYTHRODERMA

Consider MF/SS in patients with erythroderma with or without lymphocytosis

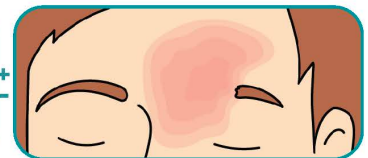**F**



FOLLICULAR LESIONS



ATYPICAL ACNE/COMEDONES



ALOPECIA

Follicular lesions and/or atypical acne, comedones or alopecia

A quick-reference guide to aid early recognition of **Cutaneous T-Cell Lymphoma (CTCL) Mycosis Fungoides/Sezary Syndrome**. Key visual cues, mnemonic aids, and differential diagnosis tips to help clinicians identify MF/SS indicators and distinguish it from inflammatory dermatoses.

**DO A BIOPSY!**